

<p>8:30-8:40 Opening 及評分說明 黃閔照 召集人 座長兼評分委員：張維君、張志隆 ★婦癌</p> <p>8:40-8:50 [1] Pembrolizumab use in an endometrial adenocarcinoma patient with nodal metastasis noted accidentally after robotic staging surgery:a one year follow up_張哲維(台北榮總)</p> <p>8:50-9:00 [2] Anti-N-methyl-D-aspartate receptor encephalitis induced by an ovarian immature teratoma: a case report and literature review_廖柔謙(臺大)</p> <p>9:00-9:10 [3] Fertility-Sparing Treatment with Hysteroscopic Tumor Resection Combined with LNG-IUD Leading to Complete Regression in a Young Woman with Early-Stage Endometrial Cancer_臧崇怡(新光)</p> <p>9:10-9:20 [4] Gestational Trophoblastic Disease in Advanced Maternal Age_戴璋瑩(台北馬偕)</p> <p>9:20-9:30 [5] Cutaneous Clues: Malignant Acanthosis Nigricans and Tripe Palms as First Signs of Recurrent Endometrial Carcinoma_左大昕(高雄長庚)</p> <p>9:30-9:40 [6] Uterine Primitive Neuroectodermal Tumor: A Rare Case_張景楮(基隆長庚)</p> <p>9:40-9:50 [7] High-Grade Large Cell Neuroendocrine Tumor of the Corpus Uteri: A Case Report and Clinical Insights_蘇思嘉(國泰)</p> <p>9:50-10:00 [8] Synchronous primary endometrial cancer and ovarian cancer: A case report and literature review_林佑庭(臺北榮總)</p> <p>10:00-10:10 [9] A 67-year-old woman with left ovarian high grade serous carcinoma stage FIGO stage IIIc_顏廷聿(台北榮總)</p> <p>10:10-10:20 [10] Preclear Clear Cell Carcinoma_柯復丞(三總)</p> <p>10:20-10:30 [11] Coexisting Right Ovarian Brenner Tumor and Mucinous Cystadenoma with Torsion: A Case Report with Surgical Management_張家甄(臺北榮總)</p>	<p>8:30-8:40 Opening 及評分說明 黃閔照 召集人 座長兼評分委員：蔡明松、郭富珍 ★產科</p> <p>8:40-8:50 [1] Delayed-Interval Delivery In Dichorionic Twin Pregnancies: A Case Presentation of 111 Latency Days_黃園詠(國泰)</p> <p>8:50-9:00 [2] Bittersweet Survival: A Case of Heart Transplantation in Peripartum Cardiomyopathy_吳宛儒(彰基)</p> <p>9:00-9:10 [3] Infective Endocarditis in Pregnancy_吳樂靈(彰基)</p> <p>9:10-9:20 [4] One-Stage Intraoperative Uterine Artery Embolization during Cesarean Delivery for Placenta Accreta_瞿心蔓(彰基)</p> <p>9:20-9:30 [5] Case Report : Trisomy 9_劉家禎(台大)</p> <p>9:30-9:40 [6] Case report---A 29-year-old woman, G2P1, GA 38+6 weeks with a history of ValN 3 and Condyloma Accuminatum_黃柏森(台大新竹分院)</p> <p>9:40-9:50 [7] Intrauterine Adhesion-induced Septated Amniotic Cavity: Ultrasonographic Findings in Second and Third Trimesters_黃若婷(高雄長庚)</p> <p>9:50-10:00 [8] Antenatal diagnosis of fetal atrial flutter with transplacental therapy, antepartum surveillance and intervention_彭冠圖(台北馬偕)</p> <p>10:00-10:10 [9] HIV infection and Pregnancy_吳孟芹(臺北榮總)</p> <p>10:10-10:20 [10] Cervical Pregnancy with Hydatiform Mole: a case report_張音瑜(嘉義長庚)</p> <p>10:20-10:30 [11] Acute placenta abruption: a case report and review_許祐瑾(台北榮總)</p>
10:30-10:40 Break	
<p>座長兼評分委員：陳國瑚、陳怡仁 ★一般婦科</p> <p>10:40-10:50 [12] Bilateral Tubal Ectopic Pregnancy in a Patient Undergoing Fertility Treatment: Diagnostic and Surgical Challenges in an Uncommon Case_游婉儒(新光)</p> <p>10:50-11:00 [13] Life-Threatening Spontaneous Uterine Rupture in a Non-Gravid, Unscarred Uterus of a Nulliparous Woman: A Case Report_謝宛玲(奇美)</p> <p>11:00-11:10 [14] Persistent Gestational Trophoblastic Disease_黃楷中(臺北榮總)</p> <p>11:10-11:20 [15] Intravascular leiomyomatosis, case report an review_李婷婷(台北榮總)</p> <p>11:20-11:30 [16] Intravenous leiomyomatosis with Budd-Chiari syndrome_林廷謙(成大)</p> <p>11:30-11:40 [17] Case discussion : recurrent acquired uterine arteriovenous malformations_林亞榮(新光)</p> <p>11:40-11:50 [18] Bilateral Ectopic Tubal Pregnancy with clomiphene induction_柯復丞(三總)</p> <p>11:50-12:00 [19] Herlyn-Wernere-Wunderlich syndrome: An unusual case with presentation of menorrhagia_柯復丞(三總)</p> <p>★內視鏡</p> <p>12:00-12:10 [20] Pregnant woman with acute abdominal pain_蕭博緯(三總)</p> <p>12:10-12:20 [21] Torsion of Parasitic Colon Adenomyoma with Acute Abdomen_陳致穎(中國附醫)</p>	<p>座長兼評分委員：黃文助、林芯仔 ★產科</p> <p>10:40-10:50 [12] total anomalous pulmonary venous return (TAPVR) : a case and review_許晏慈(臺北榮總)</p> <p>10:50-11:00 [13] Gastric Perforation in a Pregnant Patient with a History of Bariatric Surgery: A Case Report and Review of Literatures_王芷焘(成大)</p> <p>11:00-11:10 [14] Selective IUGR in MCDA twins: Three cases treatment experience and review_王韋筑(新竹台大)</p> <p>11:10-11:20 [15] Prenatal Diagnosis of Ectodactly and Syndactyly : A Case Report and Literature Review_海蒂(台北慈濟)</p> <p>11:20-11:30 [16] A case of Listeriosis during pregnancy._黃馨平(馬偕)</p> <p>★婦女泌尿</p> <p>11:30-11:40 [17] Recurrent pelvic organ prolapse associated with mesh retraction after transvaginal mesh surgery – A case report_曾瑀儒(國泰)</p> <p>11:40-11:50 [18] A Report on the Video-urodynamics Study and Treatment of a Female Patient with Primary Bladder Neck Obstruction_梁世禧(大林慈濟)</p> <p>★生殖內分泌</p> <p>11:50-12:00 [19] Recurrent pregnancy loss with paternal three-way balanced reciprocal translocation_謝禎(國泰)</p> <p>12:00-12:10 [20] Fertilization of progestin-primed ovarian stimulation protocol combined with letrozole after high dose medroxyprogesterone acetate therapy for fertility-sparing endometrial cancer : A case report_謝秉霖(三總)</p>

各位醫師，大家好：

本年度新辦理住院醫師病例報告線上討論會，除了讓住院醫生在訓練的過程中，也能有演講報告的訓練外，更希望透過病例報告討論，讓各位會員醫師們，獲取醫學新知及認識我們年輕優秀的醫師們。醫學的訓練是無止境的，只有不斷的訓練及擷取知識，才能讓病人得到安全的照護，希望本次病例報告比賽，讓住院醫師們提早融入婦產科大家庭，歡迎大家踴躍參與線上討論會，為新生代加油打氣！

理事長陳思源請假 **張維君** 副理事長代行
住院醫師教學訓練 **黃閔照**
委員會召集人
秘書長 **黃建需** 敬邀

114年度住院醫師病例討論會(全視訊)

日期：114年2月9日、2月16日（週日）兩場次

地點：全視訊

主辦單位：台灣婦產科醫學會 住院醫師教學訓練委員會

活動對象：婦產科專科醫師、住院醫師

教育積分：兩場各為婦產科A類積分3分

報名

請於2月7日(五)前完成線上報名，

俾利後續作業，報名連結：

<https://bit.ly/40xAhEA>



報名QR Code

簽到簽退

本會議有簽到及簽退，皆須完成，

始獲得專科醫師教育積分，課程

當日開放連線及簽到/退

簽到：<https://bit.ly/429ZM00>

簽退及問卷(會後開放)：<https://bit.ly/4hinkUz>

視訊連結

2月9日及2月16日視訊方式為Cisco Webex，會議連結皆為<https://bit.ly/3DQxL3B>

- 若您將以手機參與，則需要下載Cisco Webex APP後，點選視訊會議連結後跳轉至APP，輸入您希望顯示的名稱後，點選加入會議按鈕即可加入會議。
- 為保持會議品質，若有問題可於QA時間使用舉手功能，感謝您



簽到QR Code

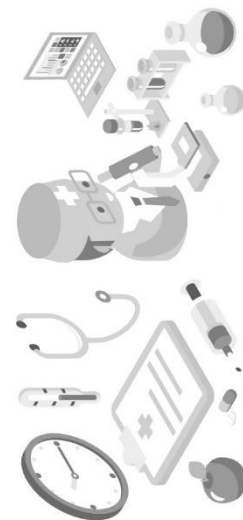


會議視訊QR Code



簽退及問卷QR Code

印刷品



台灣婦產科醫學會

台北市中山區民權西路70號5樓

TEL：02-25684819#12 FAX：02-21001476